I'm not robot
reCAPTCHA
Continue

Case study on acute pancreatitis pdf

Treatment of acute pancreatitis wikipedia.



Jochebed Gande
Nutrition Therapy 1

Case study: Pancreatitis

I. General Information
Name: patient X
Age: 31
Gender: male
Address: Sta. Cruz, Makati
Civil Status: Single
Nationality: Filipino
Religion: Catholic
Birthdate: Feb. 14, 1982
Hospital: Ospital ng Makati, Surgery Ward

Patient X was a habitual smoker since he was 15 years old. He consumes 5-10 sticks of cigarette a day. He is also a frequent alcohol drinker and he consumes 3 bottles of 500ml of red horse beer to make himself sleep.

Client doesn't have hypertension or diabetes. He has no known allergies. His last hospital visit was 2006 in Ospital ng Makati, Malugay due to tonsillitis.

II. Present illness and chief complaint/admitting impression and medical diagnosis
Abdominal pain radiating to the back

III. Past surgery and history of hospitalization
Patient X, a 31 year old male was admitted to the hospital with a complaint of abdominal pain.
1 month prior to admission, client was experiencing pain in his left upper quadrant part of the abdomen but he just ignores it. Pain was intermittent and he doesn't take in pain medication. He also experience the same kind of pain when he is full or whenever he just finished his meal. Client also feels fullness of the stomach and indigestion. Client did not go to the hospital for check-up because he did not take it seriously. He was fond fo eating foods rich in fat and he is an occasional alcohol drinker.

1 week prior to admission, pain experience became continuous even to the point that he is having a hard time to go to sleep making him feel restless. One event that he feels fullness he drank 1 bottle of coke and red horse to make himself burp. However, there was no relief of symptoms upon burping.

A day prior to admission, client experience extreme pain and he is having difficulty of breathing that is why he sought for medical assistance.

Acute pancreatitis tokyo guidelines. Case control study on acute pancreatitis. Acute pancreatitis case study answers. Acute pancreatitis treatment hindi. Case study on acute pancreatitis pdf.

A 32 -year -old arrived at the emergency department with a complaint: upper abdominal pain x 3 days x 2 episode (3 days ago) yellow urine color change and decreased urine x 2 days: PULSUBPRPPRPPPREENSE TIME 102/MIN130/ 90MMHG25/MIN97 . 2 F90% RAK/C/O hypertension instead of drugs; Normal bowel habit; No h/o loc/wrong body movements; No fever; Cough/Difficulty in respiratory tract G/C Missing: Axis, Presence/A: Softness over epigastria and right hypochondrial gut sound. 1. serum Amyl: 1524 SV/L (normal 40-140 IU/L; link â Mediaape) 2. Serum lipase: 396 SV/L (normal 0-50 SV/L; reference MediaPAPA) 3: 5.1 mg/dl (normal 0.5-1.2 mg/dL;19,900/cu.mm (normal 4,000-12,000/cu.mm) 6. â dlc: neutrophils 94% (normal 40-60%); lymphocytes 6% (20-40% normal) 7. Hemoglobin: 17.1 g/dl (normal 13-18 g/dl) 8. Blood plaques: 81,000/cu.mm (normal 150,000-400,000/cu.mm) Other tests: 1 INR: 1,072 Na+: 138 Meq/L3 K+: 4.5 Meq/L4 Common bilirubin: 6.6 mg/dL5 Breza bilirubin: 2.2 mg/dL6 Sgort (AST): 34 SV/L7 .. SGPT (ALT): 20 SV/LUSG Belly: Bass Pancreas with pancreatic collection, perhaps pancreas and herring.Fat in a small part of the liverminal pleura left with lower left cavity diagnosis: serious acute pancreas (alcohol) for acute Nile for the Nile failure due to acute Nile's failure due to acute Nile failure due to acute Nile failure ER: ICU accepted after these drugs (after consulting surgery and nephrol already): imipenem 50 mg IV IV Stat, then 250 mgA 32-year-old male presented to the emergency department with: upper abdominal pain x 3 days vomiting x 2 episodes (3 days ago) yellow urine and decreased urination x 2 days: heart rate 102/Min130/90 MMHG25/Min97.2 F90% with RAIIK /c/o hypertension and without medication; Normal bowel movement rhythm; No H/O LOC/abnormal body movement; no fever; No cough/difficulty breathing/C: Pain Jaundice: P/A: Epigastric and hypochondrial tenderness Colonic sound: B/L NVBS, B/L Same air supply, no added sounds: S1 S2 M0CNS: very intact lab reports : 1 Serum amylase: 1524 IU/L (normal 40-140 IU/L) Serum creatinine: 5.1 mg/dL (normal 0.5-1.2 mg/dL; Medscape Reference) 4. BUN: 18.9 mg/dl (normal 3-20 mg/dl; Medscape reference) 5.â TLC: 19,900/mm3 (normal 4000-12,000/mm3) 6.â DLC: neutrophils 94% (40-60% normal) Lymphocytes 6 % (normal 20-40%) 7. Hemoglobin: 17.1 g/dl (normal 13-18 g/dl) 8. Platelets: 81,000/mm3 (150,000-400,000/mm3) Other tests: 1. INR: 1072. â NA+: 138 MEQ+/L3/L4. â Total bilirubin: 6.6 mg/dl5 Direct bilirubin: 2.2 mg/dl6.” Sgot (AST) : 34 IU/L7.â.SGPT (ALT): 20 IU/LUSG Abdomen: large pancreas with localized pancreatic pouch possible pancreatitis, epomegaly and splenomegaly d and his bladder 2 = 8 with moderate ascites) Mild hepatomegaly with fatty for changes in the view of the pleura of the left rib - diagnosis with the left lower lobe: severe acute pancreatitis (alcoholic) with acute kidney involvement from the Emergency Department: admission to ICU after treatment after treatment (after surgical consultation and kidney surgery HED: Nephrology Clinic): Imipenem injection 50mg iv stat, then 250mgBDD. NS 3 Pints intravenously for 24 hours up to 5% dextrose 2 weaved intravenously for 24 hours. Opticaluron 1 leather pint. Tremadol 50 mg intravenously SOSDAILY RFTSRITT NENAL DITAT ICU: in. Tramadol replaced the injection. Petidine 50 mg intravenously SOS regular monitoring of the vital functions of DoneGBS Monitor/Result Enter the Donelab value in a few days: 1st Aerum Amilae: 97 IU/L 2. Creatinin Erum: 2.5 mg/DL 3.Bun: 8, 8, 8, 8, 8, 8, 8, 8, 8 2 mg/dl4.tlc: 33.500/cubic meter 5.

Article — Australian Journal of Herbal Medicine 2016 (1S)

Traditional naturopathic management of acute pancreatitis: A case study

Justin Sinclair [1, 2]
[1] Traditional Medicine Consultancy, Pacific Pines, QLD Australia
[2] Endeavour College of Natural Health, 100 Scarborough Street, Southport QLD Australia
Email: | sinclair@tmconsultancy.com.au

Abstract
Acute pancreatitis is a painful inflammatory disorder of variable aetiology causing abdominal pain, nausea, emesis, fever and elevated white blood cell count. It is characterised pathologically by pancreatic lytic enzymes activating the inflammatory cascade, which can lead to pancreatic necrosis, haemorrhage, and systemic inflammatory response syndrome. Although mild, this condition can be life-threatening. A patient presented with acute and persistent abdominal pain, nausea and excretion with biomedical investigations diagnosing acute pancreatitis. Naturopathic management included the use of simple crude herbal medicines, phytochemically rich foods and traditional principles to manage gastrointestinal sequalae and inflammation. The patient responded quickly and had significantly reduced gastrointestinal pain within hours of initial treatment, and was largely asymptomatic within 24 hours of commencement of naturopathic treatment. Naturopathic therapies may be an effective management strategy for acute pancreatitis in conjunction with close medical supervision.
Keywords: Acute pancreatitis, case report, case study, naturopathy, herbal medicine.

Introduction
Acute pancreatitis is a serious medical condition typically presenting to hospital emergency departments and carries with it a high mortality rate. It is considered a serious pathophysiological condition as once the pancreas is injured it can release lytic enzymes that can both enter the blood (causing severe shock) and also cause tissue digestion of the surrounding architecture.[1] Up to 80% of acute pancreatitis presentations in acute pancreatitis are attributed to biliary tract disease and acute alcohol consumption,[2] with the remaining causes being summarised in Table 1.1.

Table 1.1 Causes of Acute Pancreatitis [1, 2]
Gallstones
Infections (Mumps, Coxsackie B virus)
Drugs (steroids, carbamazepine, azathioprine, furosemide, valproic acid)
Iatrogenic (ERCP, post-surgical)
Abdominal trauma
Hyperlipidaemia
Pancreatic tumours
Hyperparathyroidism
Scorpion bite
Cardiac surgery
Idiopathic

The incidence of acute pancreatitis is rising by 3% per year in the US and Europe, believed largely to be due to the increased presentation of biliary pancreatitis,[3] with 1/5 of these patients developing necrotizing pancreatitis, with a mortality rate of 10-20%.[4] The high 10-20% mortality rate is largely due to infection of the necrotic pancreatic tissue and represents the consequences of mucosal barrier failure, small bowel overgrowth and an inflammatory response leading to bacterial translocation and sepsis.[5, 6]

Acute pancreatitis should be a clinical consideration for all patients presenting with acute abdominal pain.[7] Differential diagnoses associated with acute pancreatitis include perforated gastric or duodenal ulcer, dissecting aortic aneurysm, ischaemic bowel, intestinal mechanical obstruction (strangulation), mesenteric infarction, biliary colic and an inferior wall myocardial infarction.[7] Signs and symptoms commonly experienced include severe abdominal pain, which may radiate into the back in 50% of cases[7] due largely to retroperitoneal involvement[7] and can require parenteral analgesia. The pain is classically described as a "boring" sensation, is worsened by alcohol and is typically excruciating and may have diminished sensation.[7] Nausea and emesis are common presentations with 28% of patients also experiencing upper abdominal abdomen,[7] rigidity and tenderness. Fever may be present and investigations typically reveal a raised WBC count.[7] While such cases are highly unlikely to present to naturopathic or herbal

57 © Herbal 2015

Hemoglobin: 12.1 g/dl6.Trombocytes: 377,000/cubic meter. Mm.na+: 139 mekv/l2.k+: 5.4 mekv/l3. Bilirubin: 39 mekv/l3: 1, 3 mg/3 mg/3 mg/5.4MEKV /l3. Bilirubin: 1.3 mg/3 mg/3 mg/5.4. DL4. Direct bilirubin: 0.9 mg // L3. General -Buubin: 1.3 mg/DL4. Indirect bilirubin: 0.9 mg/DL5.PGP: 20 units/L6.PG: 32 units/L6.PG: LCAS was discontinued due to interrupted PKS. 2 days, but permanent and heavier over the past 8 hours. The pain took place in the epigastric region and left the ileum. In the morning, the episode of the g/o 1 was not combined with vomiting. A rare urination frequency and dark color of urine were noted. The character of the chair was normal. Still in bed on the icterus bunk: further diagnosis: acute pancate of cholecystitethytitetitetitis cholecystititis. Lymphocytes 12%; Eosinophils 1% platelets: 3.05 000/CU. Murin R/E: All parameters within the norm: Negan Calcium Whey: 8.1 mg/Dll: total bilirubin 2.1 mg/DL; Direct bilirubin: 1.3 mg/DL; Old: 117 units/l; Department 219 units/l; Alp 307 U / Cleaning: Two Domes of Aperture are visible on the radiograph of the abdominal cavity: there is no gas under the diaphragm (perforation is rejected).(max. 10 mm) with slightly expanded proximal CBD Vallogra (max.
12 mm); Mild calcification of the IHBD linear expansion in the VIII liver segment with minimal pleural exudate: acute mild bile pancreas with gallstones with? Galling stones at the Emergency Department: Intravenous DJ Intravenous Turulation Patient has undergone NPoinj. Tramadol 50 mg IV statin. Ondem 4 mg static intravenously. Pantoprazole 40 mg of statin intravenously.

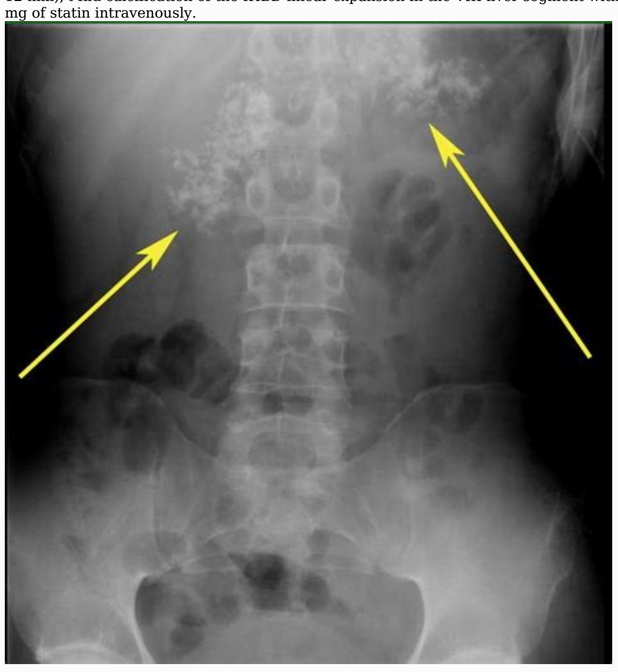

Fidine 50 mg I.V. Fenargan 25 mg intramuscularly (after 1 hour) of the above. Ns 1 Pint for 1 hour. Ns 1 Pint within 2 hours SOR decision: Admission to the surgical department after consulting with the following recommendations: advice on the likely of the need for resuscitation and catheterization of Foley. Ns 3 Pints and inject 5% DW 3 Pints within 24 hours IV CEFTRIAKSON 1 g IV BD and inject. Metronidazole 500 mg intravenous Bdinj. Pekhidin 50 mg + phenargan 25 mg / m Tidinzh. Pantoprazole 40 mg IV Blood collection Surgical: Drugs Added: 3 doses of vitamin Kketorolak instead of petididine laboratory reports after a few days: amylase: 1408 IU/L Calcium: 8.3 mg/bilirubin DL total: 2 mg/dl; Direct bilirubin: 1.1 mg/dl; ASPAT: 77 J.M./L; Alternatively 74 IU/l; Alps cholecystectomy 191 IE/L was performed: Due to the poor visualization of the Kahlo triangle, the results of laparoscopic cholecystectomy: Dischase of the gallbladder gallbladder. Total gallstones2 stonsetuse stones charde CMME CMA Eastern anesthesia caused by acute cells of inflammatory necrosis, apoptosis and bleeding in acute pancreatic inflammation. 2 of 3 cases, the following criteria: acute recurrent pancreatitis pancreatitis with at least two separate AP episodes and: complete resolution of pain (painless break ¥ 1 month between the diagnosis of acute pancreatitis)Or the normalization of serum pancreatic enzymes (amylase and lipase) before the diagnosis of another episode of acute pancreatitis and the disappearance of symptoms of complete pain, regardless of the time interval between episodes of acute pancreatitis. Etiology of acute pancreatitis.
Autoimmune (devotional) S: Spink-1 (Kajal serine protease inhibitor type 1), PRS1 (trypsinogen cation) mutation, ie. ie Genetic H: hypertriglyceridemia*, hypercalcemia, hypothermia: ERCP *D: drugs, sulfonamides, tetracycline, 6-mercaptopurine, HIV drug) How do gallstones cause pancreatitis? Theory 1: Bilt's reflux in the pancreas due to clogging of the ampoule with water 2: Theory: Intraductal hypertension extrinsic. Low obstruction of the pancreatic duct and secretion entering the interstitial tissues because alcohol causes a significant history of alcohol consumption according to the etiological diagnostic recommendations for pancreatitis.

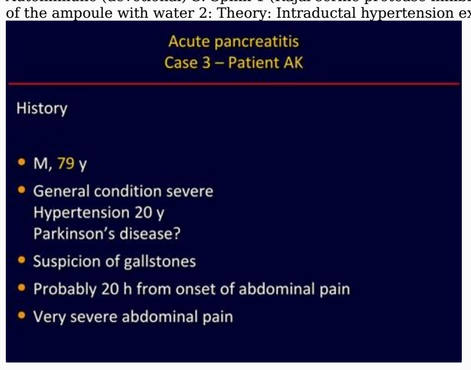

, serum triglycerides should be determined and etiology considered if > 1000 mg/dL3. A tumor of the circulatory system should be considered as a possible cause in a patient over 40 years of age. Idiopathic pancreatitis should be referred to specialist centers (if available).



2. 내원한 환자 중에서 가장 많은 문제를 가진 1 case를 선정한 후 다음과 같은 양식으로 사례를 적용하시오.

1) 응급환자 정보 조사지

등록번호 : _____ 성명 : OOO (여) 주민번호: 40세

내원일시 : 2015 년 09 월 30 일 07 시 54 분
주소 : _____ 전화번호 : _____
동반자 · 성명 : _____ □남 □여 연령:_____ 환자와의 관계 : 부모

내원경로 : ■ 직접내원 □ 외래 □ 타병원
전원병원명 : _____ □ 소견서 □ 영상검사 CD
□ 기타 _____
내원수단 : □ 119 □ 129 □ 타병원 앰뷸런스 □ 경찰차 □ 도보 ■ 기타 자동차
□ Wheea chair □ stretcher cart
질병종류 : ■ 질병 □ 질병외 □ 진료외 방문 □ 미상
손상기전 : □ 교통사고 □ 추락 □ 마고려침 □ 둔상 □ 관통 □ 기계
□ 화상 □ 물에빠짐 □ 중독 □ 기타
의도성 여부 : □ 비의도적 사고 □ 자해/자살 □ 폭력 □ 타살
□ 기타 □ 미상
사고발생 장소 : _____
사고발생시간 년 월 일 시 분

- **주증상 :** 상복부-옆구리 통증
- **발병일 :** 2015년 9월 27일 20:00
- **내원 경위 :**
9월 26일 소주1병 마셨고, 9월 27일부터 등배아파 타병원 다수차례 방문하였으나 위염이라는 설명듣고 진통제 처방받아 복용함. 진통제 복용해도 호전 없고 어제부터 양쪽 옆구리로 통증이 뻗치는 느낌 있어 본원 응급실 내원함

내원 시 활력 상태 : 혈압 148 / 94 mmHg
맥박 114 회/분
호흡 20 회/분
체온 37.4 ℃

의식상태 : ■ Alert □ Drowsy □ Stupor □ Semicoma □ Coma
과거병력 : □ 무 □ 고혈압 ■ 당뇨병 □ 결핵 □ 심장질환 □ 간염

- 1 -

Genetic testing in young patients (under 30 years of age) may be considered if there is no clear reason and there is a family history of pancreatic disease. Pathophysiology of acute pancreatitis phase -1: Premature activation of trypsin in pancreatic acinar cells causing unprotected activation of pancreatic cellsTrypsinogen trypsin) Activation of other digestive enzymes Autonomous car zymogenization inside the pancreas acute path: Upper abdomen / inflate (duration): Up to now intimate path hours: Back-related: nausea: nausea, vomiting day , anorexia, worsening factors expand the abdomen: food or drink (especially alcohol) Breastfeeding Factors: anterior protrusion, coiling signs (fetal position) pancreatitis Acute: anxiety, delusions, hallucinations Dehydration: signs of pleural effusion - usually left (occasionally).) in the abdomen: marked abdominal tenderness with voluntary and involuntary rigidity + / Signs associated with severe necrotizing pancreatitis: Kallen's sign (periibular pallor due to peritoneal hemorrhage) signs of platinum plaque platinum gray (page discoloration due to Moorone Ragia). after illness groin NT or basal base basal base base base base base base base base fever)., fever, fever, fever, fever, fever, fever, fever, acute jaundice; Bilirubin > 4; AST > 1000 cute choleist and epigastrium and biliary colic RUQ, radiating to the right shoulder or shoulder blade, increasing constant landscape and gradually increasing over 30-60 minutes; The pain radiates from the back; Vomiting and increasedLFT can be increased due to bile stones. H/O and P/S are associated with severe pain associated with significant pain from the doloral intestinal obstruction = how many, obstructive image seen to display with

predisposition to aortic aneurysm, the pain can be emitted into the lower limbs. The perforation pudding mimics cholecystitis Mall/pleural pain if pleural pain is the predominant duck symptom, lower alt> 1000 middle epigastric wall, hoarse, abnormal ECG; Myocardial infarction should be a differential diagnosis in all patients with significant pain-superior pain in the upper entrance-body, disproportionate compared to dyeing with quite benign examination.
After abdominal pain, weight loss and gonococcal abdominal noise syndrome after abdominal syndrome after RUQ pain, adnexalpneumonia fever and respiratory symptoms (shortness of breath, cough, ghost, chest pain) rlq-testa.
abdominal aorta in the epigastric region3. Mild fever: 70% hypotension: 20% jaundice: 30% gray Turner/cullen symptoms: <5% complications of acute pancreatitis Complications Acute cross pancreatitis ComplicationAtelectasis, mediastinal abscess, pneumonia, ardscardiovascular: hypotension (hypovolaemia), sudden death, pericardial effusion haematological: haemorrhagia haemorchiae emullata haemocchiae haemocchia emerratica, haemalosis emalica emerratica, haemalosis emullati di emurrete emubblica, emurshiti emurretica emerratica emerratica emerrata emerrata emerrata emufficata Emuls emulsion Emulsion emulsions emulsify emulsify Venous thrombosis (bleeding from varicose veins): defatted, nitrogenous, renal/venous thrombosis, renal duct. Acute metabolic necrosis: hyperglycemia, hypocalcemia, encephalopathy, sudden blindness (initial pancreatic lesion 1 (hemodynamic disturbance and double Punk excavation 2 (parenchymal organ failure, v. mod): 3-7 days from 3rd suspension (postcard of complications and celebrations): after 1-2 weeks, i.e. regenerative changes begin against the background of necrotic infiltration and retention fibrosis, pancreatic fibrosis.) 5. BloodSugar: insulin can cause insulin that causes beta-cell dysfunction, calcium: (hypoalbuminemia or fat necrosis) or (if the etiology is hypercalcemia) lipid profile: "hyperthyglycidemia rule as hyperthyglycidemia as hyperthygigidemia: lipid profiles:" h-hyperthyglycemia as hypermintriagidemidemidemidemide : H-hyperthyglycemia as hypertriplydemia. Rule out of hypertyglyceridaemia) Lipid profile: "Rule out of hypertyglyceridaemia") Lipid profile: "Rule out of hypertyglyceridaemia) Lipid profile: "Rule out of hypertyglyceridaemia as hyperthyglyceridaemia) Reason 6 ABG: every 12 hours 1. 3 days (to monitor acid oxygen) 7. Other: CRP, TRIPSIN, TRIPSINOGEN-2, LDH, Alipase phospholipase is more specific than amylase (therefore preferred). Lipase is produced within 4-8 hours after the onset of pain. Amylase rises within 6 hours of pain onset. Amylase may be normal due to significant destruction of the pancreas during acute inflammation. Amylase normalizes in the blood within 3-5 days, as urinary excretion increases. Lipase rises again within 7-10 days. Basal infiltrates), Left abdominal aperthragmplein X-ray (Eratto): Exclude perforated peptic ulcer with ulcers. , Obstruction of the bile ducts, the formation of pseudocysts with the abdominal cavity: this may be required so that the diagnosis is not proven and the degree is not found: peritaniatic collections; Necrosis and unusual principles of acute pancreatitis11. In the acute setting (<48–72 hours), CECT should not be performed if there is a typical clinical picture and clearly elevated levels of amylase and lipase. In the acute setting of CECT, the clinical picture and the level of amylase and lipase are unequivocal. Early visualization (within the first 72 hours) by CT can underestimate the severity of the disease. CECT will be performed pancreatic necrosis and panager necrosis after 48.72 hours, as well as acute pancreatic fluid collection. 5. Delay in CECT (> 7 2 21 days after onset of symptoms) is verySevere assessment and management, including aspiration and/or image-controlled drainage, as well as other minimally invasive types of drainage. CECT should be performed when there is a significant deterioration in the patient's condition, including a reduction in hemoglobin and hematocrit, tachycardia and hypotension, sudden changes in fever or leukocytosis. Proximal Colon Proximal Large Intestine Incision Sign Stending + Spleen Curvature Stenosis + collapsing descending colon extending from pancreatic area to colonic diaphragmatic ligament causing spleen spasm. Colon, symptom of isolated mesenteric ischemia loop obstruction localized in the intestine, seen in visceral or inflamed organs in the vicinity of body exertion to localize traumatic or inflammatory localized paralysis followed by accumulation of gas) Useful for diagnosis renal signs of the Oreol perenal inflammation in the perirenal space mild transparent inflammatory oreols in the anterior perirenal space contrasts with perirenal fat; More often on the left side, acute pancreatitis in the ultrasound pancreas (USG) (P) is swollen and fluid (the black echo band is marked with arrows) in front of the pancreas. Other visible anatomical structures are the spleen vein (UI), aorta (a) and inferior vena cava (IVC). Ultrasound examination of the pancreatic pseudocyst. Regular mass of non-disadjustment in contact with the head of the pancreas. The pancreatic tumor may be similar, but it is not as echogenic as a pseudocyst. CT Panentitis Acute Index (CTSI) for acute pancreatitis: more than 30% C)2 Komplikationen: Ein oder mehrere Pleuraexsudate, Aszites, vasküläre Komplikationen, Pulpakomplikationen und/oder gastrointestinale Beteiligung Interpretation: Pankreatitis Gesamtscore von 10: 0-3: leicht 4-7: mäßig 8-10: Score ist das Ergebnis der Punktzahl. result score (1993) Atlanta Revision (2013) akute akute Pankreatitis akute Pankreatitis Pankreatitis1. Lokale Komplikationen von I/OR1. Lokale Komplikationen I/OR2. Oder 2. Norgan. Organe (< 48 h) Blutungen GI (> 500 cm3/24 h) schwerer akuter Schock - SBPâ ¤ 90 mm HgproSchwester Organversagen > 48 hpao 2 â â â â 60 % Kreatinin ¥ 2 mg/dlga, PripendiAct; SBP, krampfhafter Blutdruck. Spezifisches Organversagen wird derzeit durch den modifizierten ScoreBisap Marshall (Bedside score for Severity of Acute Pancreatitis) definiert, Patienten mit BISAP-Scores > 0 hatten ein erhöhtes Mortalitätsrisiko und die Mortalität war ab einem Score von 3 signifikant erhöht. Die Sterblichkeit bei Ergebnis 5 betrug 22 %. Gemüse im Zusammenhang mit schweren systemischen Krankheitsmerkmalen des modifizierten Entzündungsreaktionssyndroms (SIRS) mentaler Status bei Spurenpatienten > 55 Jahre (BMI > 30 kg/m2) – Vorhandensein von > 2 der folgenden Kriterien: â PULSE > 90 bpm/minus / Erwähnung > 20/min oder paco2â2â > 32 mm Temperatur > 38 °C oder < 36 °C WBC > 12.000 oder < 4000 Zellen/mm3 oder > 10 % â UNBEOBACHTETE NETROPHILE (Bänder) Brötchen Laborergebnisse > 20 mg/dl Reisbrötchen > 44 zur Augmentation HCTeLevated Kreatininradiologie ExfusionenMehrere Ergebnisse Ergebnisse. ODER große Sammlungen / MLSEVER. Stoffwechselstörungen (Serumcalcium 7,5 mg/dl) CRP > 150 mg/l pro 1 72Does BMI affect the severity of acute pancreatitis? Fat tissue or fat releases a large number of inflammatory cytokines, which we call adipokins, 50% of TNF-A and MCP-1 release adipocytes, but it is also fatty cytokines, such as fat and adipinectin . ; Acute treatment of pancreatitis a) Initial risk assessment and stratification 1.
Hemodynamic status should be assessed immediately after hospital admission and, if necessary, resuscitation measures 2. Risk assessment should be performed to divide patients into higher and lower risk groups to relieve, to facilitate access to hospital. 3.Patitis intensive therapy department with organ failure, when possible, should be placed in an intensive care unit or intermediate therapy linking frequency + BP + MUCUTION MUCULE MUCUTION (GCS + Glucose): Examine the Cullen belly sign and the gray turn? Sensitivity to palpation? Are there any signs of peritoneum - bouncing, shielding, or tenderness from exposure? Lateral tenderness? Temperature measurement requires additional oxygen tracheal intubation for ARDS or severe encephalopathy c) fluid in acute pancreatitis. In the case of small benefits, except for large amounts (hypotension and tachycardia), RL may be required, and the need for fluid in the replacement of isotonic crystalloids may be preferable within 6 hours after the next 24-48 hours . Field) Blood products in acute pancreatitis: in the case of hemorrhagic pancreatitis.30% (alcohol abuse): MgSO4: 2 g i.v. PiggybackF) Pain management of acute pancreatitis in the past Morphine is blamed for causing spasm of the sphincter of Oddi (analgesic of choice was pethidine). a course of APmetamisole (2 g/8 h IV) vs. morphine (10 mg/4 h s.c.): metamizole provided more frequent and faster pain relief than continuous intravenous (IV) infusions of procaine: a patient receiving procaine was likely to require additional analgesics and had relatively less pain relief procaine (2 g/24 h as continuous intravenous infusion)) compared to pentazocine (IV bolus every 6 hours): patient receiving procaine more often required additional analgesics (98% vs. 44%) G) Antiemetics in acute pancreatitis H) Nasogastric suction in acute pancreatitis Flatulence I) Antibiotics for acute pancreatitis Indicated for extrapancreatic infection such as cholangitis, catheter-related infections, bacteremia, urinary tract infections, pneumonia. Routine use of prophylactic antibiotics in patients with severe acute pancreatitis is not recommended. Antibiotics are not recommended in patients with avascular necrosis to prevent the development of infected necrosis.
Infected necrosis should be considered in patients with pancreatic or extrapancreatic necrosis that worsens or does not resolve after 7 to 10 days of hospitalization. In these patients, either (i) initial CT-guided fine needle aspiration (FNA).Start immediately if there is no nausea and vomiting and the abdominal pain has subsided. Small to eat low -fat infectious complications. Avoid parenteral nutrition, unless the elditer road is inaccessible, unacceptable or does not meet calorie requirements. It seems that enteral and noble nutrition in the river basin has similar effectiveness and safety.
Acute pancreatitis is a proven method of treating acute pancreatitis. All of them showed unsatisfactory results in large randomized research. Criteria of subtitle of necrotizing pancreatitis in the case of acute pancreatitis without symptoms of bile ducts and the ability to tolerate oral fluid pancreatitis with minimal abdominal pain and the ability to tolerate oral fluids to resemble ERCP in severe pancreas cysts. Surgical consultation with bile duct inflammation H or bile duct obstruction is compulsory in case of suspected lining of cholelithiasis of pancreatitis, accordingly missing in the laboratory.Evidence of permanent biliary obstruction. In the absence of cholangitis and/or yellow, if choledocolitis is suspected, choledocolitiasis screening should use MRCP or endoscopic ultrasound (EUS) rather than ERCP diagnosis. Medicines (NSAIDs) should be used to treat pancreatitis after ERCP to prevent severe pancreatitis after ERCP. Acute pancreatitis (AP) surgery in patients with mild AP diagnosed with gallstones should have a cholecystectomy before prescribing to prevent bee recurrence. Until the active inflammation has disappeared and the fluid flow has disappeared or stabilized and/or increased in stable patients with infected necrosis, surgical, radiographic and/or endoscopic drainage should be delayed for more than 4 weeks to ensure the liquefaction of the content and the formation of fiber. tissue.We walls around necrosis (masonic necrosis). Symptomatic patients with infected necrosis are preferred to minimally invasive necrosectomy methods. He is the curator of the epomodicin orthopedic department. Find and share simpler ways to make complex health problems simple. She also likes to write poems, listen to music and act. FacebookTwitTretwitter